



Keywords

Quadriceps contracture,
Puppies, Stifle, Skeletal
development, Anatomy.

CORRESPONDING AUTHOR

Maria Elena Andreis
mariaelena.andreis@unimi.it

JOURNAL HOME PAGE

riviste.unimi.it/index.php/haf

Stifle anatomic, tomographic and biomechanical features of growing dogs affected by quadriceps contracture.

M.E. Andreis^{1,*}, M. Di Giancamillo², L.M. Carnevale², U. Polito¹, M.C. Veronesi², A. Di Giancamillo¹, S.C. Modina¹

¹ Department of Health, Animal Science and Food Safety, Università degli Studi di Milano, Via Celoria 10, 20133 Milan, Italy.

² Department of Veterinary Medicine, University of Milan, Via Celoria 10.

Quadriceps contracture is a debilitating and uncommon condition, mostly affecting young dogs. It can be congenital (Stead et al., 1977) or acquired (Leighton, 1981; Bardet and Hohn, 1983; 1984) and is reported to induce muscular hypotrophy/fibrosis, progressive degenerative joint disease, bone hypoplasia and limb hyperextension (Bardet and Hohn, 1983; 1984). The aim of this study was to elucidate anatomic, tomographic and biomechanical features of stifles affected by quadriceps contracture.

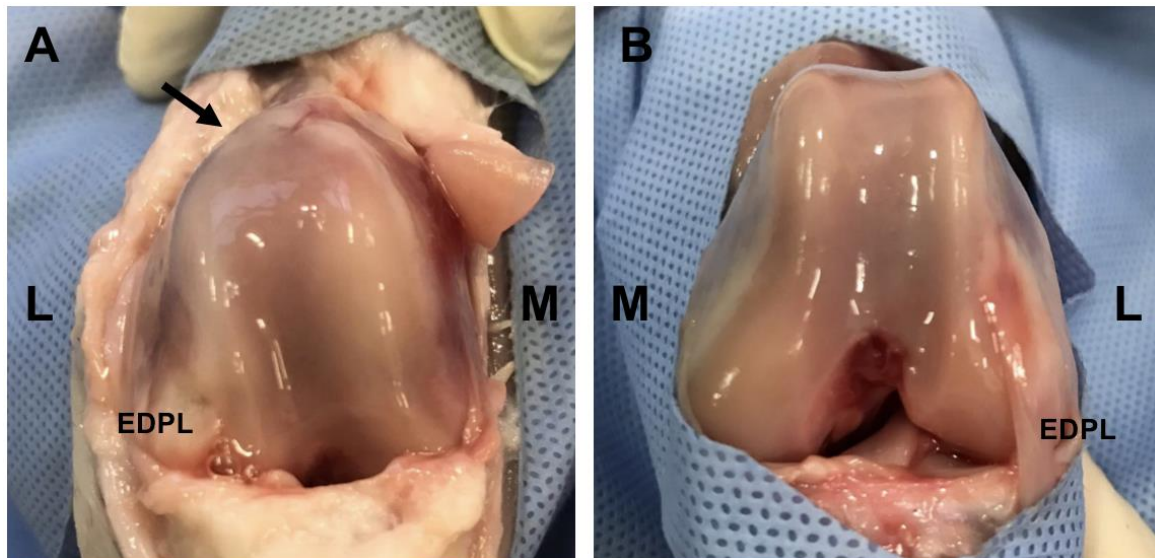
Seven 2-month-old dead Dobermann Pinschers with unilateral quadriceps contracture were included. Before gross anatomic evaluation, all stifles underwent Computed Tomography before and after intra-articular administration of iodinated contrast medium (Samii et al., 2004). Images were acquired in double positioning (stifle extension and flexion) to identify articular cartilage, Ossification Centres' (OCs) and menisci abnormalities, which were compared between affected and unaffected limbs (Figure 1).

In all affected limbs the stifle was back-turned, the distal femur was extra-rotated and the patella was luxated proximo-medially. Severe lack of physiological stifle movements (rolling, gliding, spinning) was observed, so that affected joints could not be flexed. The articular cartilage of the femur was flattened and irregular in thickness, the femoral trochlea was hypoplastic and sloping, the menisci were misshaped. The OC of the distal femur and proximal tibia were misshaped; the tibial plateau was oriented caudodorsally-cranioventrally and significantly smaller ($P < 0,05$).

Quadriceps contracture influenced stifle development. The action of quadriceps insertion on the tibia prevented normal development of the plateau, causing wedging and abnormal orientation. Constant compression also induced external rotation of the distal femur (unable to develop distally) and patellar luxation, ending up in genu recurvatum. Static compression was likely responsible for femoral trochlea hypoplasia, articular cartilage and meniscal deformation, due to the lack of physiological stifle movements.

Quadriceps contracture induces severe alterations of stifle development in affected puppies. Histology, histochemistry and immunohistochemistry may better define the nature of such bone, cartilage and meniscal alteration.

Figure 1: Gross anatomic evaluation of the stifle in a puppy affected by unilateral quadriceps contracture (distal epiphysis of the femur). A: affected stifle; B: unaffected stifle. In the affected stifle the femoral condyles are flattened, the trochlea is hypoplastic and sloping (black arrow). M: medial; L: lateral; EDPL: extensor digitorum pedis longus.



References

- Bardet, J.F., Hohn, R.B., 1983. Quadriceps contracture in dogs. *Journal of the American Veterinary Medical Association* Sep;183(6):680-685.
- Bardet, J.F., Hohn, R.B., 1984. Subluxation of the hip joint and bone hypoplasia associated with quadriceps contracture in young dogs. *Journal of the American Animal Hospital Association* May/Jun;20(3):421-428.
- Leighton, R.L., 1981. Quadriceps contracture (ischemic contracture of the quadriceps), in Bojrab M (ed): *Pathophysiology in Small Animal Surgery*. Philadelphia, Lea and Febiger, pp550-552.
- Samii, V.F., Dyce, J., 2004. Computed tomographic arthrography of the normal canine stifle. *Veterinary Radiology&Ultrasound* 45:402-406.
- Stead, A.C., Camburn, M.A., Gunn, H.M., Kirk, E.J., 1977 Congenital hindlimb rigidity in a dog. *Journal of Small Animal Practice* 18:39-46.